



PATIENT PRESENTING CLINICAL SIGNS

Cash Griffin

History: Gallop rhythm noted over the last few years. Assess prior to anesthesia for a mass removal.
-Abnormal PE/Chem/CBC/UA Results: Chem 17: ALP 1,156. CBC - Normal, Lytes - Normal

SPECIES ELECTROCARDIOGRAPHIC FINDINGS

Canine

A six lead ECG is available at 25mm/s; 20mm/mV. The average heart rate is 100bpm (range 58-136bpm). The rhythm is sinus in origin, with a p for every QRS complex and vice versa. The P wave morphology is positive with a normal dimension. Normal PR. The QRS morphology is positive with normal dimension. MEA is normal. No ectopic beats, pauses or dysrhythmias observed.

BREED

Boston Terrier

ECG diagnosis: Normal sinus rhythm with profound respiratory variation.

SEX ECHOCARDIOGRAM FINDINGS

Male Neutered

2D, m-mode, color flow and doppler imaging is available. Mild diffuse thickening of mitral valve leaflets with no prolapse into the left atrial lumen. Mild eccentric mitral regurgitation with mild left atrial dilation. Normal MR velocity. Normal LV diameter with adequate myocardial function. The tricuspid valve appears normal with no tricuspid regurgitation. Normal right atrial and ventricular diameter and morphology indicating no overt evidence of pulmonary arterial hypertension. The pulmonic and aortic valves are normal in morphology and mobility. Normal pulmonic and aortic outflow velocities with laminar flow. No obvious aortic or pulmonic insufficiency. No pericardial or pleural effusion noted. No obvious cardiac masses.

AGE

10 years

WEIGHT

34lbs

CARDIAC CHART

INTERPRETED BY

Maggie Machen Lamy, DVM, DACVIM (Cardiology)

CANINE CARDIAC PARAMETERS	MR VMAX (m/s)	TR VMAX (m/s)	LA/AO (Boon method)	LA/AO (Heart Base; Swe)	FS (%)	EF (%)	EPSS (cm)
NORMAL PARAMETER	4.5-5.5	<2.7	1.3	<1.6	28-40	40-100	<0.6
PATIENT	5.0		1.3	1.4	31	60	0.3
CANINE CARDIAC PARAMETERS	HR (BPM)	AV VMAX (m/s)	PV MAX (m/s)	BODY WEIGHT (kg)	LA 2D short axis Base view (cm)	LVIDd Avg; 2D and m-mode short axis (cm)	LVIDs Avg; 2D and m-mode short axis (cm)
NORMAL PARAMETER	50-100	0.7-1.7	0.7-1.6	BELOW	BELOW	BELOW	BELOW
PATIENT		1.7	1.0	15.4	2.5	3.9	2.7
*Normal chamber parameters expressed as a mean value (SD)							
BODY WEIGHT DEPENDENT PARAMETERS							
*Note: All measurements based upon multi-modal images and methods. An average value is reported.							
Adapted from June Boon, Veterinary Echocardiography, 1998							
Rishniw M and Hollis NE, J Vet Intern Med 2000; 14:429-435							
Hansson et al, Vet Rad and Ultrasound 2002							
Bonagura et al. Echocardiography: principles of interpretation, Vet Clin North Am 15:1177, 1995							
				3	1.27 (5.3)	2.46 (2.46)	1.36 (5.5)
				5	1.40 (4.5)	2.74 (5.2)	1.60 (4.7)
				10	1.50 (3.8)	3.27 (3.5)	2.06 (3.1)
				15	1.83 (2.0)	3.71 (2.4)	2.43 (2.1)
				20	2.02 (1.9)	4.14 (2.2)	2.80 (2.0)
				25	2.18 (2.4)	4.48 (2.9)	3.10 (2.5)
				30	2.33 (3.3)	4.83 (3.9)	3.39 (3.4)
				35	2.48 (4.3)	5.17 (5.0)	3.69 (4.5)
				40	2.62 (5.2)	5.48 (6.1)	3.96 (5.4)
				50	2.88 (7.1)	6.07 (8.3)	4.46 (7.4)

IMAGING PERFORMED BY

Karen Ebersole, DVM, DABVP

HOSPITAL NAME

Scanvet

REFERRING VET

Dr. Saunders

INVOICE

32359

DATE

8/15/23



PATIENT

Cash Griffin

SPECIES

Canine

BREED

Boston Terrier

SEX

Male Neutered

AGE

10 years

WEIGHT

34lbs

INTERPRETED BY

Maggie Machen Lamy,
DVM, DACVIM
(Cardiology)

IMAGING PERFORMED BY

Karen Ebersole,
DVM, DABVP

HOSPITAL NAME

Scanvet

REFERRING VET

Dr. Saunders

INVOICE

32359

DATE

8/15/23

INTERPRETATION OF THE FINDINGS & FURTHER RECOMMENDATIONS

Chronic degenerative valve disease causing mild mitral regurgitation. Lack of significant left atrial enlargement indicates the current risk for complication is low. No concurrent issues such as systolic dysfunction or pulmonary hypertension are noted in this study.

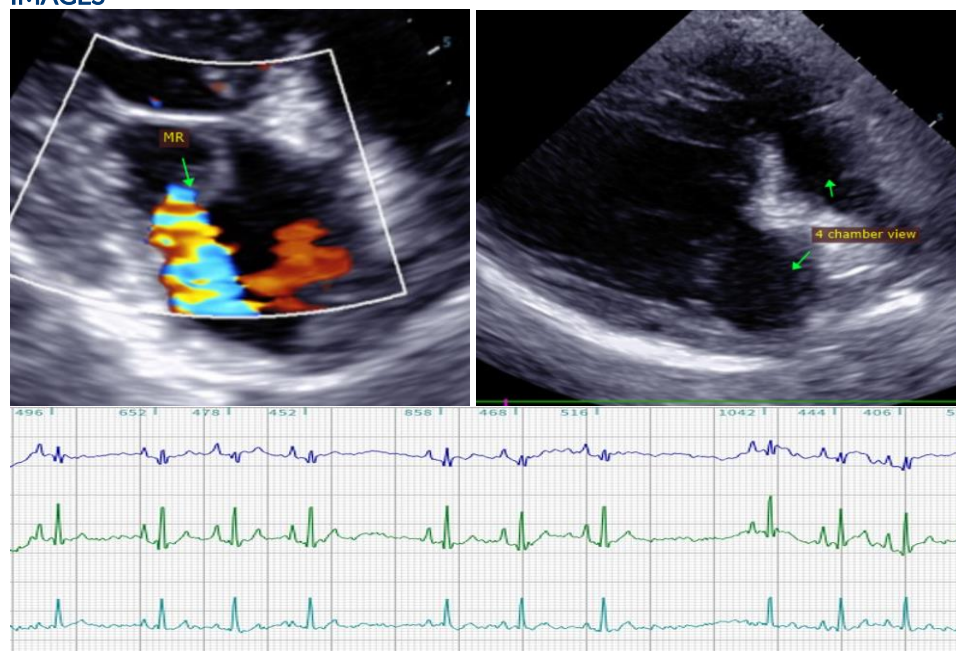
The ECG is most consistent with a respiratory sinus arrhythmia due to high vagal tone. This is benign in origin; however, premedicating with a vagolytic is recommended.

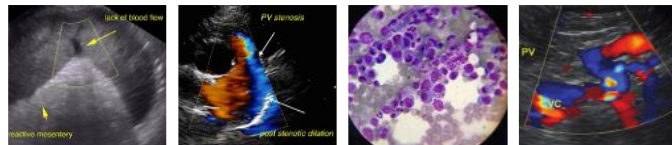
In a dog with no significant left atrial enlargement, no cardiac medications are clearly indicated. Assessment of progression in the future will help predict long term prognosis, which is highly variable at this stage (B1). Omega fatty acid supplementation and mild salt restriction may be of some long-term benefit. Monitor for development of a cough, labored breathing, exercise intolerance or collapse episodes.

Anesthetic risk is considered mild if needed. Premedicate with a vagolytic. Cardiac protective drug choices (opioid/benzodiazepine premedication, propofol or alfaxalone induction, isoflurane gas) are recommended. Pre-oxygenate for 5-10 minutes prior to induction. Monitor for arrhythmias, hypotension, and hypoxia both intra and post-operatively and intervene as necessary. Mild IV fluid restriction is recommended to avoid fluid overload.

Recommend conservative monitoring with a recheck echocardiogram in 6-12 months, sooner if any development of clinical signs.

IMAGES





PATIENT

Cash Griffin

The information and recommendations provided are based on the images presented by the referring veterinarian. No evaluation can be communicated regarding pathology that was not visible in the image/video clips provided.

SPECIES

Canine

Thank you for this referral. This report was generated using transcription software, and minor dictation errors may be present. If the clinical or image interpretation does not parallel your findings or if I can be of any further assistance, please contact me.

BREED

Boston Terrier

Maggie Machen Lamy, DVM
Diplomate of the American College of Veterinary Internal Medicine (Cardiology)
info@sonopath.com

SEX

Male Neutered

AGE

10 years

WEIGHT

34lbs

INTERPRETED BY

Maggie Machen Lamy,
DVM, DACVIM
(Cardiology)

**IMAGING
PERFORMED BY**

Karen Ebersole,
DVM, DABVP

HOSPITAL NAME

Scanvet

REFERRING VET

Dr. Saunders

INVOICE

32359

DATE

8/15/23